

High energy focused shock wave therapy accelerates bone healing

A blinded, prospective, randomized canine clinical trial

N. R. Kieves¹; C. S. MacKay²; K. Adducci¹; S. Rao¹; C. Goh¹; R. H. Palmer¹; F. M. Duerr

¹Colorado State University Veterinary Teaching Hospital, Department of Clinical Sciences; ²Colorado State University, Department of Environmental and Radiological Health Sciences

Keywords

Tibial plateau leveling osteotomy, bone healing, shock wave therapy, canine cruciate disease

Summary

Objectives: To evaluate the influence of shock wave therapy (SWT) on radiographic evidence of bone healing after tibial plateau leveling osteotomy (TPLO).

Methods: Healthy dogs between two to nine years of age that underwent TPLO were randomly assigned to receive either electro-hydraulic SWT (1,000 shocks) or sham treatment (SHAM). Treatment or SHAM was administered to the osteotomy site immediately postoperatively and two weeks postoperatively. Three blinded radiologists evaluated orthogonal radiographs performed eight weeks postoperatively with both a 5-point and a 10-point bone healing scale. Linear regression analysis was used to compare median healing scores between groups.

Results: Forty-two dogs (50 stifles) were included in the statistical analysis. No major complications were observed and all osteotomies healed uneventfully. The median healing scores were significantly higher at eight weeks postoperatively for the SWT group compared to the SHAM group for the 10-point ($p < 0.0002$) and 5-point scoring systems ($p < 0.0001$).

Clinical significance: Shock wave therapy applied immediately and two weeks postoperatively led to more advanced bone healing at the eight week time point in this study population. The results of this study support the use of electro-hydraulic SWT as a means of accelerating acute bone healing of canine osteotomies. Additional studies are needed to evaluate its use for acceleration of bone healing following fracture, or with delayed union.

(3–8). Complications associated with the creation of an osteotomy include delayed unions, malunions, and implant failure (8–10). Strategies to avoid such complications related to bone healing are continually being evaluated. The TPLO provides a relatively standardized procedure allowing the study of the efficacy of therapies intended to promote bone healing in a clinical setting.

A shock wave is a sonic pulse (acoustic pressure or sound wave) with defined physical characteristics of a high peak pressure (up to 50 MPa), a fast initial rise in pressure (<10ns), a low tensile amplitude (up to 10 MPa), a short life cycle (<10ms), and a broad frequency (16–20MHz) (11–13). Shock wave therapy (SWT) has been utilized for many indications in dogs including tendinopathies, pain control, arthritis management, and bone healing (14–20). In humans, SWT was initially used in urology for disintegration of urinary stones (lithotripsy). Current musculoskeletal applications now include plantar fasciitis, epicondylitis of the elbow, calcifying and non-calcifying tendinopathies, delayed and nonunion fractures, as well as avascular necrosis of the femoral head (21).

Shock wave therapy has been shown to stimulate bone healing in dogs, horses, and humans (12, 14, 15, 22–26). Canine specific literature includes only four studies showing limited support for the use of SWT for bone healing in dogs (14, 15, 25, 27). Hastening of bone healing after TPLO would be beneficial to the individual patient to potentially decrease osteotomy complications and to shorten the convalescent period allowing earlier return to optimal function. Furthermore, TPLO can be viewed as a model to answer the broader question of whether SWT has a positive ef-

Correspondence to:

Felix Duerr, DVM, MS, DACVS-SA, DECVS, DACVSMR
James L. Voss Veterinary Teaching Hospital
Colorado State University
300 W. Drake Rd
Fort Collins, CO 80523
United States
Phone: +1 970 297 5000
Fax: +1 970 297 1205
E-mail: Felix.Duerr@colostate.edu

Vet Comp Orthop Traumatol 2015; 28: 425–432

<http://dx.doi.org/10.3415/VCOT-15-05-0084>

Received: May 13, 2015

Accepted: July 27, 2015

Epub ahead of print: October 9, 2015

Introduction

Delayed bone healing of naturally occurring fractures and osteotomies required for the treatment of angular limb deformities and cranial cruciate ligament disease can lead to patient morbidity, revision pro-

cedures, and decreased patient function, which places additional cost and care burden upon the pet owner (1, 2). Cranial cruciate ligament disease, one of the most common causes of hindlimb lameness in canine patients, is frequently treated by tibial plateau levelling osteotomy (TPLO)

fect on bone healing. To the authors' knowledge, no study has objectively evaluated the effect of SWT on acute bone healing in canine clinical patients.

The aim of this study was to evaluate if SWT promotes acute bone healing in dogs undergoing TPLO for naturally occurring cranial cruciate ligament disease. We hypothesized that SWT would result in greater radiographic healing scores at eight weeks postoperatively when compared to a sham-treatment.

Materials and methods

This study was designed as a randomized, blinded (radiographic evaluation), prospective clinical study of client-owned dogs that were presented for surgical treatment of naturally occurring cranial cruciate ligament disease. If owners elected to pursue TPLO, they were offered the option to enrol in this study. The Colorado State University Institutional Animal Care Use Committee approved the study, and owner consent was a prerequisite for study enrolment. Hospital fees for SWT and serial postoperative radiographs were waived and a financial incentive^a was provided as a study enrolment benefit. This study was divided into two phases: Phase 1 was a pilot study to determine if there was preliminary evidence to suggest that SWT accelerated radiographic healing to justify a larger scale study. The results of Phase 1 were utilized to perform a power calculation for Phase 2.

Animals

Dogs (2–9 years of age) with a tibial plateau angle (TPA) of 20–34° and owners agreeing to pre-determined re-evaluations were considered for enrolment in the study. Dogs were excluded for any of the following: suspected systemic disease based upon laboratory evaluation (haematology, chemistry panel); steroid administration within 30 days of surgery; intra- or postoperative major complications (fibular fracture, implant failure, or any complication requiring

revision surgery); lack of osteotomy compression; tibial conformation requiring frontal or transverse plane correction resulting in an osteotomy gap.

Surgical treatment

A board certified surgeon or a surgical resident under the supervision of an ACVS-Diplomate performed the TPLO procedures. A full medial-parapatellar arthrotomy was performed to confirm the diagnosis of cranial cruciate ligament disease and to evaluate the intra-articular structures. Partial meniscectomy of the damaged portion of the meniscus was performed when a meniscal tear was identified; no meniscal treatment was performed if the medial meniscus was intact. Tibial plateau levelling osteotomy was performed with the aid of a jig and gauze packing of the proximal tibia as previously described (28, 29). Locking plates with locking screws for all proximal screw holes and conventional screws for the distal screws were used^b (29). Plate size was selected at the surgeon's discretion. All osteotomies were compressed with either the aid of large reduction forceps placed across the osteotomy or placement of at least one conventional screw in compression. The TPA was measured for surgical planning and immediately after surgery. Duration of postoperative non-steroidal anti-inflammatory drug use was recorded for each patient and treatment duration was categorized as zero to 14 days, 15 to 30 days, or greater than 30 days.

Treatment groups

Randomization into the treatment group (SWT) or sham group (SHAM) was performed only for cases that were presented for surgical correction of the first stifle. Allocation for Phase 1 was performed by pulling a card out of a box that contained an equal number ($n = 6$) of yes/no cards. If an animal was presented for TPLO of the second stifle, the animal was assigned to the opposite treatment of the first procedure (i.e. if the dog had SWT for the first

stifle, SHAM treatment would be applied for the second stifle). For Phase 1, a sample size of 12 dogs was chosen based on funding available for this portion of the study. The minimum number of cases enrolled for Phase 2 was determined based on sample size calculation derived from Phase 1 data and available funding. Randomization was performed via coin-flip for Phase 2.

In the SWT group, electro-hydraulic SWT was applied with a commercially available shock wave system^c immediately postoperatively and at the time of suture removal (approximately 2 weeks postoperatively). The first SWT treatment was applied under general anaesthesia and the second SWT treatment was applied under sedation (dexmedetomidine [2.5–7.5 µg/kg] and butorphanol [0.15–0.3 mg/kg] or hydromorphone [0.05 mg/kg] intravenously). A total of 1,000 shocks (setting: E6; pulse/min: 360) were applied at each treatment along the osteotomy site identified by palpation of the plate and review of the radiographs. Care was taken to avoid application of shocks over the bone plate; 500 shocks were applied from the caudo-medial aspect using the 5 mm trode and, then, 500 shocks were applied from cranio-lateral aspect using the 20 mm focal spot trode, both at the E6 setting. The incision site was covered with an adhesive dressing^d to maintain sterility. Acoustic transmission gel^e was applied directly to the treatment head. The treatment heads were slowly moved while applying the treatment (approximate treatment area 5–8 cm). Sham treatment was performed as described above, but the SWT device was not activated.

Outcome assessment

For Phase 1, radiographs were performed preoperatively and at zero, four, six, eight, and 10 weeks postoperatively. For Phase 2, radiographs were only performed preoperatively, immediately postoperatively, and eight weeks postoperatively. To obtain

a PulseVet provided the financial incentive to the owners and it was used to reduce their cost of the surgery at CSU.

b Depuy Synthes[®]Vet, Paoli, PA, USA

c VersaTron 4Paws device: PulseVet Technologies, Alpharetta, GA, USA

d Primapore: Smith and Nephew, St. Petersburg, FL, USA

e Sonotech Lithoclear: Magnaflux, Bellingham, WA

radiographs of similar positioning at each time point, animals were sedated (dexmedetomidine [2.5–7.5 µg/kg] together with butorphanol [0.15–0.3mg/kg] or hydromorphone [0.05mg/kg] intravenously), and the same exposure settings, beam and limb position were used for all radiographs of a single patient. Postoperative radiographs included standard orthogonal TPLO-views with the mediolateral view being slightly obliqued to provide clear visualization of the osteotomy site (i.e. beam oriented directly through the osteotomy for mediolateral view; medial cortex visualized without plate overlay for the caudocranial view; ► Figure 1).

For the initial assessment of radiographs in Phase 1, scoring was performed using a novel 10-point scoring system developed specifically for evaluation of TPLO radiographs by combining appropriate features of previously described scoring systems (30–32). The descriptor terminology of the novel scoring system was designed by group consensus of the authors. Both the cranio-caudal and mediolateral projection were utilized in the scoring of the radiographs. In Phase 2 of the study, the radiographs were also scored using a previously reported 5-point scale (31, 32). For the 10-point scale, points were assigned for *cortical continuity* (0 = no cortical continuity; 1 = one continuous cortex; 2 = 2 continuous cortices), *osteotomy line visibility* (0 = osteotomy line visible; 1 = osteotomy line barely visible; 2 = no osteotomy line visible), *subjective degree of callus formation or remodelling* (0 = none; 1 = minimal; 2 = moderate; 3 = remodelled; 4 = healed), and *degree of rounding of the distal ‘step’ at the osteotomy-site* (0 = none; 1 = mild; 2 = significant). The maximum score for the utilized scoring system was 10 (0 = no healing and 10 = complete remodelling). In Phase 2, scoring was performed using the 10-point scale as well as a 5-point scale based on a previously reported radiographic healing system that used a scale of 0–4 (0 = no healing, 1 = 1–25% healing, 2 = 26–50% healed, 3 = 51–75% healed, 4 = 76–100% healed) (31, 32). Three board-certified radiologists evaluated all radiographs including radiographs from Phase 1. Hence, all radiographs were evaluated by three observers with both scoring systems. To accomplish

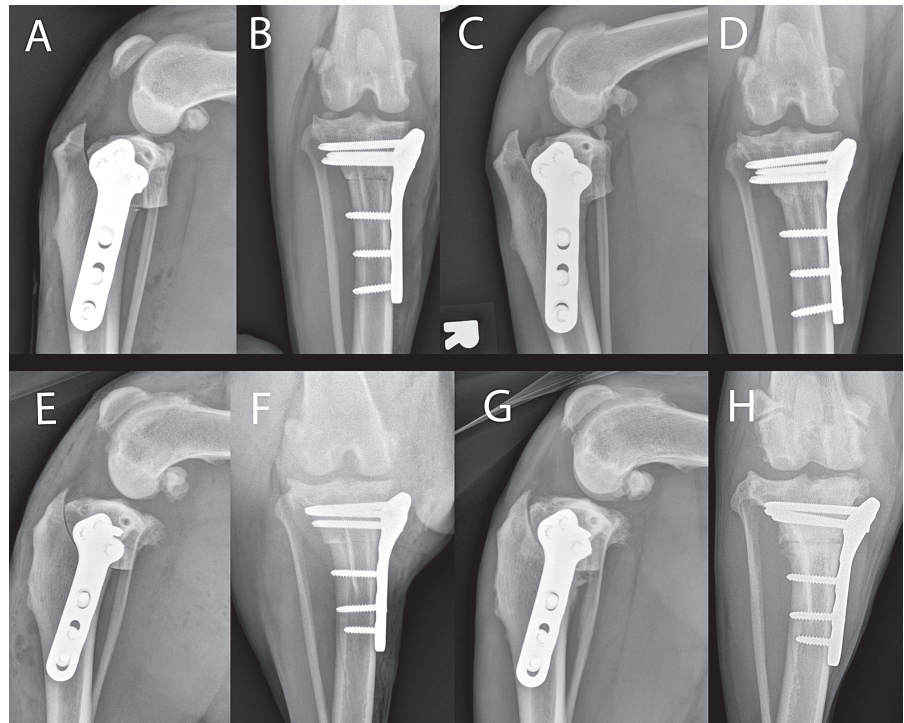


Figure 1 A, B, E, F) Immediate postoperative radiographs. C, D, G, H) Six week postoperative radiographs. A–D) Radiographic images from a dog in the shock wave therapy group with a score of 7 out of 10, and E–H) are from a dog in the sham treatment group dog with a score of 3 out of 10.

blinding, all radiographs were labelled in random order and identifying features (such as date and case number) were removed.

Statistical analysis

All analyses were performed using commercially available software^f. For both phases, median radiographic scores were calculated and used to evaluate healing. Scores from both scoring systems (5-point and 10-point scales) were converted into ranks to perform parametric analysis with linear regression analysis. This analysis was performed with ‘treatment group’ as predictor variable in the model within each scoring system. For Phase 1, ‘week’ was also used as a predictor variable in the model and an interaction term between ‘treatment group’ and ‘week’ was included to evaluate the effect of SWT with time (in weeks) on bone healing considering repeated measures across time points. A Fisher’s exact test was performed

to compare groups with respect to achievement of complete healing at each time point. For Phase 2, a repeated measures from the same dog with both scoring systems, and measured by three observers, was taken into account in the linear regression analysis. Power and sample size calculation were performed after completion of Phase 1 of the study to determine the sample size needed to detect a difference for bone healing at the eight week time point between groups. A student’s t-test was utilized to evaluate age of dogs at the time of surgery, weight of dogs at the time of surgery, days to follow-up examinations, and pre- and postoperative TPA between treatment groups. Bone plate size and duration of non-steroidal anti-inflammatory drug treatment were analysed by analysis of variance. Statistical significance was set as $p \leq 0.05$.

Results

Phase 1

Twelve dogs (13 stifles) of various breeds (5 mixed breed dogs, 4 Labrador Retrievers, 1

^f SAS 9.3; SAS Institute Inc., Cary, NC, USA

English Bulldog, 1 Australian Shepherd, 1 Husky) with a mean body weight of 32.3 ± 5 kg and a mean age of 5 ± 1.7 years were enrolled in the first phase of the study. Seven of the dogs were spayed females (3 stifles in the SHAM group, 4 stifles in the SWT group) and five were castrated males (2 stifles each in the SHAM and SWT group and one enrolled in both groups because of bilateral, staged TPLO, and hence it was assigned to the opposite treatment group for the second procedure). Six stifles were assigned to the SWT group and seven stifles to the SHAM group. One animal in the SHAM group had a trochleoplasty due to an intra-operative finding of a shallow trochlear groove. One animal in the SWT group was treated with an extracapsular anti-rotational suture applied through a loop in a tension band (utilizing the anti-rotational pin) because of excessive internal stifle rotational instability noted intra-operatively after completion of the TPLO procedure. These dogs were excluded from further statistical analysis given the additional procedures performed.

All animals were evaluated radiographically at each of the five postoperative time points (immediately postoperatively week 0, 4 week at 28 ± 1 days, 6 week at 42 ± 2 days, 8 week at 57 ± 1 day, 10 week at 70 ± 1 days). The median healing scores were significantly higher at weeks four, six, eight, and 10 weeks when compared to week zero in both groups (SWT and SHAM; $p < 0.0001$ for all comparisons). At week four, the SWT group showed a significantly higher median healing score than the SHAM group ($p = 0.0135$), but not for any of the other time points. At the eight-week time-point, healing scores were 7.43 ± 2.23 for the SHAM group and 9.33 ± 0.52 for the SWT group resulting in a calculated power of 0.59. To accomplish a power of 0.8 (CI 95%) at the eight-week time point, the calculated sample size was 12 dogs per group.

Phase 2

Based on the sample size calculation, expected variation between study patients and available funding, an additional 32 dogs were enrolled resulting in a total of 44 dogs (53 stifles prior to exclusions) of vari-

ous breeds (14 mixed breed dogs, 12 Labrador Retrievers, 3 each of German Shepherd Dog and Golden Retriever, 2 each of Australian Shepherd and English Bulldog, and 1 each of American Staffordshire terrier, Belgian Malinois, Catahoula Leopard Dog, German Shepherd Dog mix breed, Labradoodle, Siberian Husky, Newfoundland, and Swiss Mountain Dog). One dog in the SHAM group was treated with an extracapsular anti-rotational suture applied through a loop in a tension band (utilizing the anti-rotational pin), because of excessive internal stifle rotational instability noted intra-operatively after completion of the TPLO procedure. This dog was excluded from further statistical analysis given the additional procedure performed. Including this dog, a total of three dogs were excluded from further statistical analysis; two dogs from Phase 1 and the third from Phase 2. This resulted in a total of 42 dogs (50 stifles) used in further statistical analysis.

The mean body weight of dogs enrolled in Phase 1 and 2 was 33.3 ± 9.9 kg with a mean age of 5.6 ± 1.9 years. There was no significant difference between the SWT and SHAM groups for age or weight ($p = 0.9359$, $p = 0.7870$). A total of 26 dogs were spayed females (15 stifles in the SHAM group, 12 stifles in the SWT group); 15 dogs were castrated males (5 stifles in the SHAM, 7 in the SWT group); and one dog in the SHAM group was a male.

Including Phase 1 and 2 dogs, nine dogs underwent staged, bilateral TPLO procedures and were assigned to the opposite treatment group for the second procedure. Forty-eight of the plates used were 3.5 mm TPLO plates (3.5 mm standard plates: 14 SWT, 11 SHAM; 3.5 mm 'broad' plates: 7 SWT, 12 SHAM; 3.5 mm 'small' plates: 2 SWT, 2 SHAM), and two were 2.7 mm plates (1 SWT, 1 SHAM). There was no significant difference between treatment groups in plate size utilized ($p = 0.9945$). All dogs treated with a non-steroidal anti-inflammatory drug were given carprofen[®] at ≤ 2.2 mg/kg PO q12 hours. There was no significant difference between groups for duration of carprofen administration (0–14

days: 21 SWT, 22 SHAM; 15–30 days: 3 SWT, 2 SHAM; >30 days: 0 SWT, 2 SHAM; $p = 1.000$).

In addition to the TPLO, one dog underwent simultaneous TPLO plate removal from the contralateral, non-clinical limb at the owners' request. There was no significant difference in pre- or postoperative TPA between groups with a mean preoperative TPA of $27.2^\circ \pm 3.1$ (range: 20 – 32°) and postoperative of $5.1^\circ \pm 2$ (range: 1 – 10°) ($p = 0.1678$ preoperatively, $p = 0.9910$ postoperatively). Nine stifles in each treatment group had damage to the medial meniscus and a partial meniscectomy was performed. Three patients developed mild seroma formation (two in the SHAM and one in the SWT group) and two animals partially removed the skin sutures prematurely (one in each group). All dogs tolerated SWT treatment with no adverse events noted.

Clients were instructed to return their dogs for an initial re-examination two weeks following surgery as is standard protocol for suture removal. At this visit, sutures were removed from the incision if healed and dogs underwent either shock-wave or sham treatment. This visit was performed a mean of 15 ± 1.5 days (range: 7–19 days) postoperatively. There was no significant difference between the SHAM and SWT groups for the number of days following surgery of this initial examination ($p = 0.4152$). All animals were then evaluated radiographically at approximately eight weeks after surgery (mean: 8.1 weeks ± 3 days, range: 7–9.2 weeks), with no significant difference between groups ($p = 0.3468$) for number of days following surgery.

The median healing scores were significantly higher eight weeks postoperatively for the SWT group compared to the SHAM group for the 5-point and 10-point scoring system ($p < 0.0002$, $p < 0.0001$) (► Figure 2). One dog in the SHAM group was re-evaluated at 12 weeks postoperatively as the osteotomy was only 75% healed at the eight week examination. At this examination the osteotomy was deemed to be healed and no additional evaluation was performed. Based on progressive healing and good clinical function, no further examinations

g Rimadyl: Zoetis, Florham Park, NJ, USA

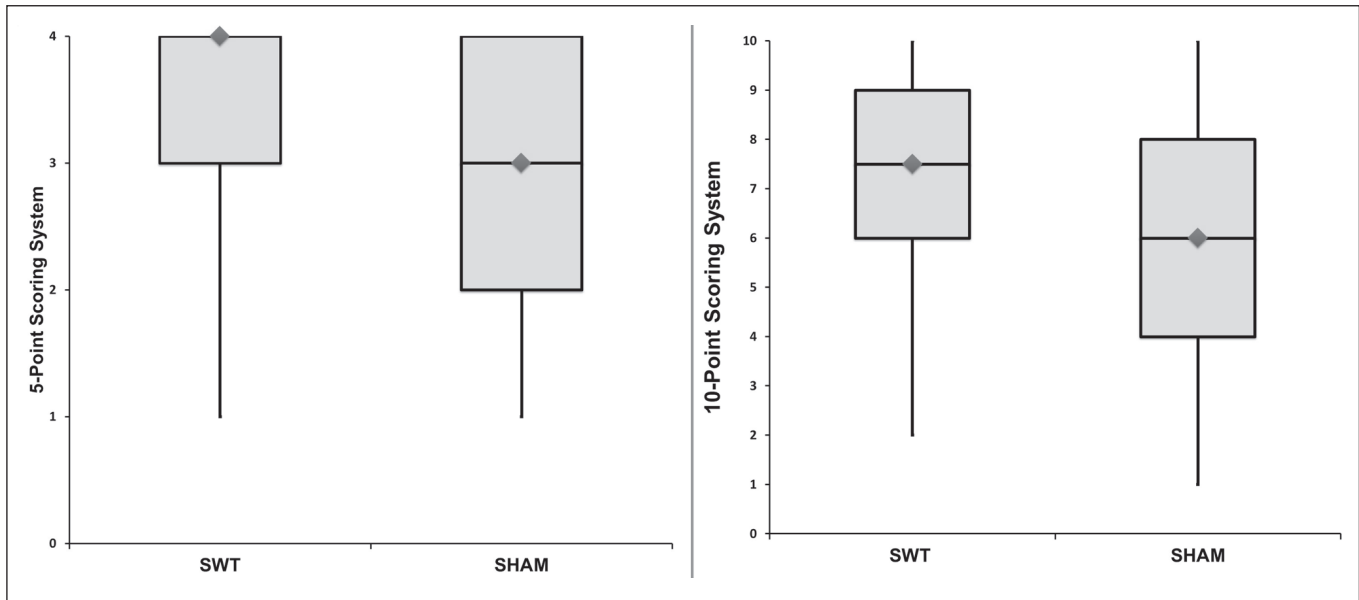


Figure 2 These box and whisker plots show radiographic healing scores for the 5-point scale (left) and 10-point scale (right) at eight weeks postoperatively. The boxes represent the upper and lower quartile score, with the median being shown by the horizontal line. The vertical lines represent the full range of scores.

were performed on the remainder of the animals.

Discussion

This is the first study evaluating the effect of SWT on acute bone healing in a larger population of clinical canine patients after routine TPLO. In our study population (Phase 2), two sessions of electro-hydraulic SWT significantly increased radiographic bone healing scores at eight weeks postoperatively. These results strengthen the available literature and support the use of SWT for promotion of acute bone healing in dogs.

Several studies have shown a beneficial effect of SWT on bone healing for delayed unions and enhancement of acute fracture healing in humans and animals (12-15, 21-25, 27, 33, 34). While the exact mechanisms of action are unknown, the creation of microfractures, stimulation of neovascularization and osteoblastic activity, increased nitric oxide levels and osteogenic growth factor activation (such as transforming growth factor beta 1, vascular endothelial growth factor, and bone morphogenic protein 2), as well as osteogenic differentiation of mesenchymal stem cells

have been proposed (21, 23, 24, 33, 35, 36). The ideal dosing frequency and optimal energy density to enhance fracture healing with SWT, however, remains unknown and a wide variety of protocols have been reported in the literature (12, 14, 15, 21-26). We selected our treatment protocol based upon the available literature, cost associated with treatment, and client convenience. The device utilized for the study allowed the operator to choose between six settings, each representing different energy levels that could not be altered. The maximum power setting (E6) was used in the present study. According to the manufacturer this unit emits 0.365 mJ/mm² (Personal communication: A. Lock, PulseVet Technologies, Alpharetta, GA, USA. July 2015).

Several studies have investigated the effect of SWT on acute fracture healing. Wang and colleagues found that a single, immediate postoperative treatment (2,000 shocks, 0.18 mJ/mm²) of electro-hydraulically generated SWT increased radiographic callus formation and histologic cortical bone formation at 12 weeks in a canine tibial fracture model (15). A study utilizing an acute femoral fracture model in rabbits used 2,000 shocks (0.47 mJ/mm²) one week after fracture repair, which re-

sulted in improved bone strength, and a higher number of new vessels and osteogenic markers (vascular endothelial growth factor, endothelial NOS, proliferating cell nuclear antigen, and bone morphogenic protein 2) in the treatment group (36). To evaluate the influence of different energy levels, a follow-up study was performed comparing low-energy (2,000 shocks, 0.18 mJ/mm²) and high-energy (4,000 shocks, 0.47 mJ/mm²) SWT to a control group in the same model. Shock wave therapy was again administered one week after the fracture was created. The high-energy group showed significantly increased callus formation, higher peak load, peak stress, modulus of elasticity and bone mineral density values compared to the low-energy and control groups (37).

Researchers have also evaluated the difference in healing of acute fractures with two or three treatments (at 7 and 21 days or 7, 21, and 35 days; 5,000 shocks; 0.32 mJ/mm²). Treatment was improved with the use of SWT compared to a control group, however, no additional benefit was observed with a third treatment in rabbits (38). The application of a single, postoperative treatment (6000 shocks, 0.62 mJ/mm²) significantly reduced the nonunion rate from 20% (control group) to 11%

(treatment group) in humans with acute fractures (39).

Shock wave therapy has been used in clinical veterinary cases to treat delayed unions: Drum treated delayed union at least 15 weeks after TPLO in three dogs with the same device utilized in this study with a single treatment of 750 shocks (14). This single treatment improved lameness scores and progression of radiographic healing in all dogs (14). Johannes and colleagues investigated SWT in a nonunion canine model in Beagle dogs and concluded that SWT accelerates bone healing of hypertrophic nonunions (25). Barnes and colleagues did not find any improvement in bone densitometry with SWT using the same device as used in our study in dogs undergoing a tibial tuberosity advancement procedure at the eight week time point compared to untreated controls (27). The difference in study findings may be explained with the difference in osteotomy (contact osteotomy versus gap) of the TPLO and tibial tuberosity advancement procedures, the low sample size in the TTA study, and the use of different outcome measures to evaluate bone healing (27).

In summary, the available data from animal research and clinical application in humans suggests that either one or two treatments at the highest setting are indicated. It is unknown which of the two treatments produced the beneficial effects in our study. We selected a quite low number of shocks compared to previous reports as clients are charged per shock and hence treatment cost rises with the number of shocks applied, and we wanted to mimic a true clinical application of SWT. Following common clinical practice protocols in the human and veterinary medical fields, we did not adjust our total shock dose based on the size of the patient. However, in the authors' opinion, the size of the treatment area should be described when reporting treatment with non-coupled shock wave devices that are moved during treatment. It is important to realize that variables including energy flux density, number of shocks and treatments, device-type, treatment area, and type of treatment (i.e. moving the shockwave during application or a fixed device) may explain conflicting research results from previous

studies. The amount of shocks applied in our study was probably on the low end of the beneficial spectrum, especially given that we used a non-coupled device.

Shock waves show a high rate of attenuation through air but 1000 times lower attenuation in the body (11). Hence, the use of acoustic coupling gel is recommended. The gel should ideally be applied to the treatment head directly to accomplish improved acoustic coupling, as performed in our study (40). The effect of shock waves applied over an implant is unknown, but reflection of the shocks by the implant is anticipated. Hence, application of SWT over the implant was avoided as reported in clinical application in humans (39).

The 10-point radiographic scoring system utilized was developed to evaluate bone healing specifically following TPLO surgery. Previously reported radiographic scoring systems frequently utilize presumably less sensitive scales with three to five assigned grades that are not specific to TPLO-healing and also not validated for the specific indication of TPLO evaluation (31, 32, 41). The new scoring system was created using a larger scale and evaluation of TPLO-specific features such as rounding of the distal osteotomy "step" seen on mediolateral projections. However, rounding of the distal "step" may not be a feature of bone healing but rather represent bone remodelling. Use of a 10-point scoring system was chosen in an attempt to make radiographic evaluation more sensitive for detection of changes in healing. However, this modified 10-point scoring system has not been validated, which is why a previously utilized 5-point scoring system was also used to score all radiographs in Phase 2 of the study. Regardless of the scale chosen, based on our experience, it is very important to perform precise radiographic positioning during the radiographic evaluations to allow clear visibility of the cortices and osteotomy.

Several study design features should be considered when interpreting these data. We minimized individual patient healing factors by narrowing inclusion criteria such as health status and age. Additionally, the surgical procedure was standardized with all dogs undergoing full arthrotomies, locking plate fixation, gauze packing and

compression of the osteotomy to decrease variability in other factors that could affect healing. Though no significant difference was seen between patient age or weight, these factors cannot be completely accounted for in a clinical setting. Additionally, dogs of various breed and sex were enrolled, which may be a source of variability in the results. Ideally, a single sex and breed would be utilized in such a study to eliminate this variable. Another limitation of this study is the variability in patient size and plate size selected. While different plate sizes were utilized, the clinician selected the size of the plate based upon the individual signalment and body condition of the dog, suggesting that a similar stimulation for bone healing can be expected. No significant difference between the SWT and SHAM groups was found in plate size distribution, therefore, this probably did not affect the results of the study. Other factors, such as activity level and exercise restriction, that may even be more likely to play a role in osteotomy healing, were also not accounted for. For these reasons, a larger number of dogs were enrolled in the study.

The TPLO model utilized to investigate the effects of SWT on bone healing in this study was intended to resemble an acute fracture model. While it would have been ideal to perform serial radiographic evaluations (4, 6, 8, and 10 weeks) in both phases of this study, this was not feasible in the larger patient group of phase 2 for financial reasons. All dogs showed signs of progressive radiographic healing and subjectively adequate clinical healing at their final eight-week re-examination. An alternative approach would have been to follow all dogs out to complete radiographic healing, allowing for evaluation of time until union between groups. This is particularly worthy of discussion since the majority of our cases were considered to be sufficiently healed at eight weeks, and to not require further radiographic evaluation. Obviously, this interpretation depends on the individual surgeon's preference and may vary amongst different observers. The lack of osteotomy complications and non-unions is consistent with the current literature and not surprising (6, 29, 42, 43). However, delayed unions have been reported in the literature and a strategy to avoid this compli-

cation is desirable. The goal of this study was to determine if healing can be promoted with SWT. In Phase 1 we demonstrated accelerated early healing at the four-week time point, and in Phase 2 more advanced healing was seen at the eight-week time point. We chose the eight-week clinical time point because it is commonly used in clinical practice, which has been utilized in previous studies evaluating clinical bone healing (43). Based on the current study, it may be justifiable to perform routine radiographic evaluation TPLO cases receiving SWT at the six-week time point rather than the eight-week time point.

In summary, the results of this study confirm that SWT increases radiographic bone healing scores after routine TPLO. However, further studies are necessary to determine the ideal frequency and number of treatments needed, as well as the number of shocks per treatment. The described protocol did not appear to have any detrimental effects and therefore, can be recommended for clinical use. Based on the results of this study and the available literature, SWT may be considered as a treatment option if accelerated bone healing is desired, though further studies are required to investigate its use in other clinical situations such as acute fractures and delayed and non-unions.

Acknowledgements

This study was funded by PulseVet Technologies. This study was presented, in part, at the 2014 Veterinary Orthopedic Society and World Veterinary Orthopaedic Congress, Breckenridge, CO; March 1–8, 2014

Conflict of interest

The authors report no conflicts of interest.

References

- Jackson LC, Pacchiana PD. Common complications of fracture repair. *Clin Tech Small Anim Pract* 2004; 19: 168–179.
- Millis DL. Bone- and non-bone-derived growth factors and effects on bone healing. *Vet Clin North Am Small Anim Pract* 1999; 29: 1221–1246.
- Johnson JA, Austin C, Breur GJ. Incidence of canine appendicular musculoskeletal disorders in 16 veterinary teaching hospitals from 1980 through 1989. *Vet Comp Orthop Traumatol* 1994; 7: 56–69.
- Powers MY, Martinez SA, Lincoln JD, et al. Prevalence of cranial cruciate ligament rupture in a population of dogs with lameness previously attributed to hip dysplasia: 369 cases (1994–2003). *J Am Vet Med Assoc* 2005; 227: 1109–1111.
- Whitehair JG, Vasseur PB, Willits NH. Epidemiology of cranial cruciate ligament rupture in dogs. *J Am Vet Med Assoc* 1993; 203: 1016–1019.
- Wilke VL, Robinson DA, Evans RB, et al. Estimate of the annual economic impact of treatment of cranial cruciate ligament injury in dogs in the United States. *J Am Vet Med Assoc* 2005; 227: 1604–1607.
- Comerford EJ, Smith K, Hayashi K. Update on the aetiopathogenesis of canine cranial cruciate ligament disease. *Vet Comp Orthop Traumatol* 2011; 24: 91–98.
- Fitzpatrick N, Solano MA. Predictive variables for complications after TPLO with stifle inspection by arthrotomy in 1000 consecutive dogs. *Vet Surg* 2010; 39: 460–474.
- Pacchiana PD, Morris E, Gillings SL, et al. Surgical and postoperative complications associated with tibial plateau leveling osteotomy in dogs with cranial cruciate ligament rupture: 397 cases (1998–2001). *J Am Vet Med Assoc* 2003; 222: 184–193.
- Stauffer KD, Tuttle TA, Elkins AD, et al. Complications associated with 696 tibial plateau leveling osteotomies (2001–2003). *J Am Anim Hosp Assoc* 2006; 42: 44–50.
- Ogden JA, Toth-Kischkat A, Schultheiss R. Principles of shock wave therapy. *Clin Orthop Relat Res* 2001; 387: 8–17.
- Furia JP, Rompe JD, Cacchio A, et al. Shock wave therapy as a treatment of nonunions, avascular necrosis, and delayed healing of stress fractures. *Foot Ankle Clin* 2010; 15: 651–662.
- Zelle BA, Gollwitzer H, Zlowodzki M, et al. Extracorporeal shock wave therapy: current evidence. *J Orthop Trauma* 2010; 24 Suppl 1: S66–70.
- Drum MG. Extracorporeal shockwave therapy for treatment of delayed TPLO healing in dogs. *Veterinary Orthopedic Society 39th Annual Conference Abstracts*; 2012 March 3–10; Crested Butte, CO. *Vet Comp Orthop Traumatol* 2012; 25: A14.
- Wang CJ, Huang HY, Chen HH, et al. Effect of shock wave therapy on acute fractures of the tibia: a study in a dog model. *Clin Orthop Relat Res* 2001; 387: 112–118.
- Danova NA, Muir P. Extracorporeal shock wave therapy for supraspinatus calcifying tendinopathy in two dogs. *Vet Rec* 2003; 152: 208–209.
- Gallagher A, Cross AR, Sepulveda G. The effect of shock wave therapy on patellar ligament desmitis after tibial plateau leveling osteotomy. *Vet Surg* 2012; 41: 482–485.
- Kirkby KA, Lewis DD. Canine hip dysplasia: reviewing the evidence for nonsurgical management. *Vet Surg* 2012; 41: 2–9.
- Venzin C, Ohlerth S, Koch D, et al. Extracorporeal shockwave therapy in a dog with chronic bicipital tenosynovitis. *Schweiz Arch Tierheilkd* 2004; 146: 136–141.
- Becker W, Kowaleski MP, McCarthy RJ, et al. Extracorporeal shockwave therapy for shoulder lameness in dogs. *J Am Anim Hosp Assoc* 2015; 51: 15–19.
- Wang CJ. Extracorporeal shockwave therapy in musculoskeletal disorders. *J Orthop Surg Res* 2012; 7: 11.
- Alvarez RG, Cincere B, Channappa C, et al. Extracorporeal shock wave treatment of non- or delayed union of proximal metatarsal fractures. *Foot Ankle Int* 2011; 32: 746–754.
- Elster EA, Stojadinovic A, Forsberg J, et al. Extracorporeal shock wave therapy for nonunion of the tibia. *J Orthop Trauma* 2010; 24: 133–141.
- Schaden W, Fischer A, Sailler A. Extracorporeal shock wave therapy of nonunion or delayed osseous union. *Clin Orthop Relat Res* 2001; 387: 90–94.
- Johannes EJ, Kaulesar Sukul DM, Matura E. High-energy shock waves for the treatment of nonunions: an experiment on dogs. *J Surg Res* 1994; 57: 246–252.
- McClure SR, Van Sickle D, White MR. Effects of extracorporeal shock wave therapy on bone. *Vet Surg* 2004; 33: 40–48.
- Barnes K, Lanz O, Were S, et al. Comparison of autogenous and cancellous bone grafting and extracorporeal shock wave therapy on osteotomy healing in the tibial tuberosity advancement procedure in dogs. *Radiographic densitometric evaluation. Vet Comp Orthop Traumatol* 2015; 28: 207–214.
- Slocum B, Slocum TD. Tibial plateau leveling osteotomy for repair of cranial cruciate ligament rupture in the canine. *Vet Clin North Am Small Anim Pract* 1993; 23: 777–795.
- Kowaleski MP, Boudrieau RJ, Beale BS, et al. Radiographic outcome and complications of tibial plateau leveling osteotomy stabilized with an anatomically contoured locking bone plate. *Vet Surg* 2013; 42: 847–852.
- Corrales LA, Morshed S, Bhandari M, et al. Variability in the assessment of fracture-healing in orthopaedic trauma studies. *J Bone Joint Surg Am* 2008; 90: 1862–1868.
- Duerr FM, Duncan CG, Savicky RS, et al. Comparison of surgical treatment options for cranial cruciate ligament disease in large-breed dogs with excessive tibial plateau angle. *Vet Surg* 2008; 37: 49–62.
- Krotscheck U, Thompson MS, Ryan KK, et al. Comparison of TPA, bone healing, and intra-articular screw placement using conventional nonlocked application of surgeon-contoured versus locked application of precontoured TPLO plates in dogs. *Vet Surg* 2012; 41: 931–937.
- Xu ZH, Jiang Q, Chen DY, et al. Extracorporeal shock wave treatment in nonunions of long bone fractures. *Int Orthop* 2009; 33: 789–793.
- Griffin XL, Smith N, Parsons N, et al. Ultrasound and shockwave therapy for acute fractures in adults. *Cochrane Database Syst Rev* 2012; 2: CD008579.
- Wang CJ, Yang KD, Ko JY, et al. The effects of shockwave on bone healing and systemic concentrations of nitric oxide (NO), TGF-beta1, VEGF and BMP-2 in long bone non-unions. *Nitric Oxide* 2009; 20: 298–303.
- Wang CJ, Wang FS, Yang KD. Biological effects of extracorporeal shockwave in bone healing: a study in rabbits. *Arch Orthop Trauma Surg* 2008; 128: 879–884.
- Wang CJ, Yang KD, Wang FS, et al. Shock wave treatment shows dose-dependent enhancement of bone mass and bone strength after fracture of the femur. *Bone* 2004; 34: 225–230.

38. Hsu RW, Tai CL, Chen CY, et al. Enhancing mechanical strength during early fracture healing via shockwave treatment: an animal study. *Clin Biomech (Bristol, Avon)* 2003; 18: S33-39.
39. Wang CJ, Liu HC, Fu TH. The effects of extracorporeal shockwave on acute high-energy long bone fractures of the lower extremity. *Arch Orthop Trauma Surg* 2007; 127: 137-142.
40. Neucks JS, Pishchalnikov YA, Zancanaro AJ, et al. Improved acoustic coupling for shock wave lithotripsy. *Urol Res* 2008; 36: 61-66.
41. Hoffer MJ, Griffon DJ, Schaeffer DJ, et al. Clinical applications of demineralized bone matrix: a retrospective and case-matched study of seventy-five dogs. *Vet Surg* 2008; 37: 639-647.
42. Bergh MS, Peirone B. Complications of tibial plateau levelling osteotomy in dogs. *Vet Comp Orthop Traumatol* 2012; 25: 349-358.
43. Conkling AL, Fagin B, Daye RM. Comparison of tibial plateau angle changes after tibial plateau leveling osteotomy fixation with conventional or locking screw technology. *Vet Surg* 2010; 39: 475-481.